

Paratubal Cyst

David Quinlan, MB, BCh, FRCSC

Victoria BC

A 40-year-old woman presented with intermittent episodes of lower abdominal pain. She had two previous vaginal deliveries and had no menstrual abnormality. Seven years ago, a left ovarian cyst was noticed on ultrasound.

No adnexal abnormality was palpable on examination. Transvaginal ultrasound revealed a 5.6 cm simple cyst in the left adnexa (Figure 1). This cyst was followed with serial clinical examination and ultrasound. There was no significant change in the appearance or size of the cyst. During this period of conservative management the lower abdominal discomfort became more frequent and persistent.

Laparoscopy revealed torsion of a left paratubal cyst (Figure 2), which was simply removed using PDS endoloops on the pedicle. Both ovaries and the pelvic peritoneum were normal.

The pathology confirmed a benign paratubal cyst. The patient's symptoms completely resolved.

Consent to publish these images has been obtained from the patient.

J Obstet Gynaecol Can 2006;28(4):275

Figure 1

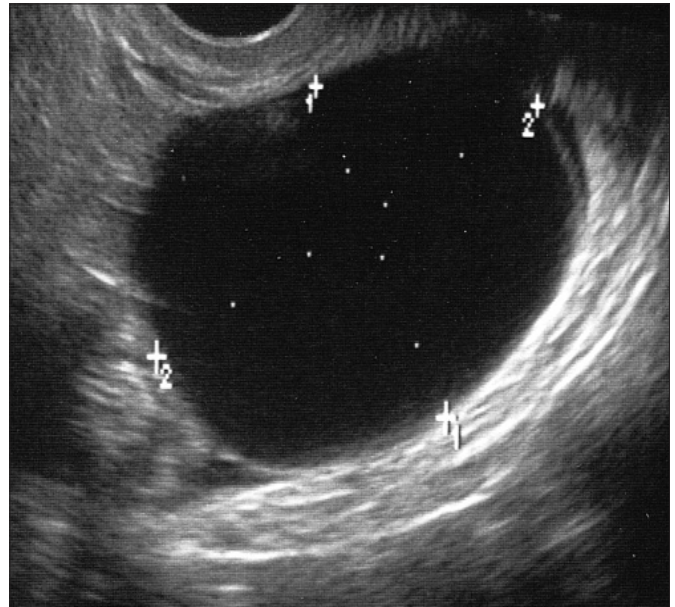


Figure 2

