

SOGC Statement: Prenatal Screening Update during the COVID-19 Pandemic

Authors: François Audibert, Annie Ouellet, Nan Okun, R. Douglas Wilson

May 7, 2020 (Reaffirmed August 20th, 2021)

Introduction

The COVID-19 pandemic has already had a profound impact on both pregnant women and professionals involved in pregnancy care.¹⁻⁵

Here we propose to discuss briefly how the prenatal screening strategies in Canada could be adapted to this unprecedented situation, in order to minimize time exposure of patients and health care providers and limit the number of screening tests / visits while maintaining an excellent level of screening for fetal aneuploidy and other anomalies.

This document does not intend to replace or update the existing guidelines,⁶ but should be seen as a statement on the potential adaptations of prenatal screening policies in Canada in the particular context of the COVID-19 pandemic.

First trimester ultrasound

First trimester ultrasound is the cornerstone of early screening for a large number of fetal anomalies including aneuploidy. Where available with adequate expertise, the first trimester ultrasound (11 to 14 weeks' gestation) offers many advantages beyond the value of nuchal translucency for aneuploidy

screening, including accurate dating of pregnancy, determination of twin chorionicity, and early detection of major structural abnormalities (anencephaly, limb reductions, omphalocele, megacystis, cystic hygroma, etc.).^{7,8} The SOGC guidelines recommend that “every effort should be made in order to provide high-quality first trimester ultrasound to all pregnant women in Canada”.⁶

In the context of the COVID-19 pandemic, the practice of prenatal ultrasound requires careful attention in order to minimize risks for patients and healthcare providers, as described in a recent ISUOG consensus statement.⁹ Provided that adequate preventative measures and infection screening policies are in place, we suggest that the provision of first trimester ultrasound should be maintained and even expanded in the pandemic context. While some providers may have questioned the benefit of maintaining the same standard of ultrasound in order to minimize exposures, we strongly believe that the balance of benefits and risks is still in favor of universal first trimester comprehensive ultrasound performed optimally between 11-14 week’s gestation. In order to provide screening ultrasound services with a high clinical value, earlier “dating” scans should be avoided if the 11-14 weeks ultrasound is regionally available, in the absence of a clinical indication such as bleeding or a previous ectopic pregnancy.¹⁰ The only situation where the provision of the first trimester ultrasound should be questioned in the current context is a suspected or confirmed COVID-19 infection. In such a case, we endorse the ISUOG (International Society of Ultrasound in Obstetrics and Gynecology) recommendation to reschedule combined test in 2 weeks if still within gestational-age window or offer NIPT/serum screening and detailed scan in 3–4 weeks after quarantine.⁹

Non-invasive aneuploidy prenatal screening: maternal serum screening or cell-free placental DNA-based

Maternal serum screening is still the first-tier prenatal aneuploidy screening strategy in most provinces in Canada. The maternal serum / plasma can be used as part of: (1) first-trimester combined screening (FTS, using NT ultrasound with free-beta hCG and PAPP-A, with the optional addition of AFP and PIGF (enhanced FTS)¹¹; (2) second trimester only quadruple screening (QUAD); or (3) integrated prenatal screening with the association of FTS and QUAD (two-step screening).

Integrated screening can be offered with NT ultrasound (full IPS) or without (Serum IPS, or SIPS). NT ultrasound is not mandatory but greatly improves the performance of serum-based screens, in addition to offering advantages beyond screening for common aneuploidies.¹² Full IPS has the advantage over FTS of decreasing the screen-positive from about 4-5% to 1-2%, but it has the disadvantages of delaying results and requiring additional visits.

Furthermore, if NIPT (see below) is offered as a second-tier test after a positive FTS, the false positive rate of this “contingent” screening process becomes very low.

Aneuploidy screening based on cell-free circulating placental DNA (cfDNA / non-invasive prenatal testing (NIPT)), has high detection with low false positive rates for the common aneuploidies. Over the past five years, NIPT has become a major player in the field of prenatal screening and can be offered as a second-tier test, after a positive conventional screening result, or as a first-tier test for those who meet certain criteria or are willing to pay. During this pandemic, all patients should be made aware of the availability of cell free DNA testing for common aneuploidies as an alternative with improved positive predictive

value. The major limitations of NIPT are the test cost, its cost-covered availability in the public healthcare system, and important technical pitfalls including low DNA fetal fraction, maternal or placental mosaicism, vanishing twin pregnancy or maternal malignancy leading to complex or 'no result' reports in 2-3% of screened patients. It is important to emphasize that the use of NIPT for genomic screening beyond the common aneuploidies (trisomy 21/18/13) is not currently recommended. It is also important to emphasize that NIPT detects only common aneuploidies, which represents only a fraction of clinically relevant fetal anomalies that can otherwise be detected by ultrasound and/or invasive genetic testing.

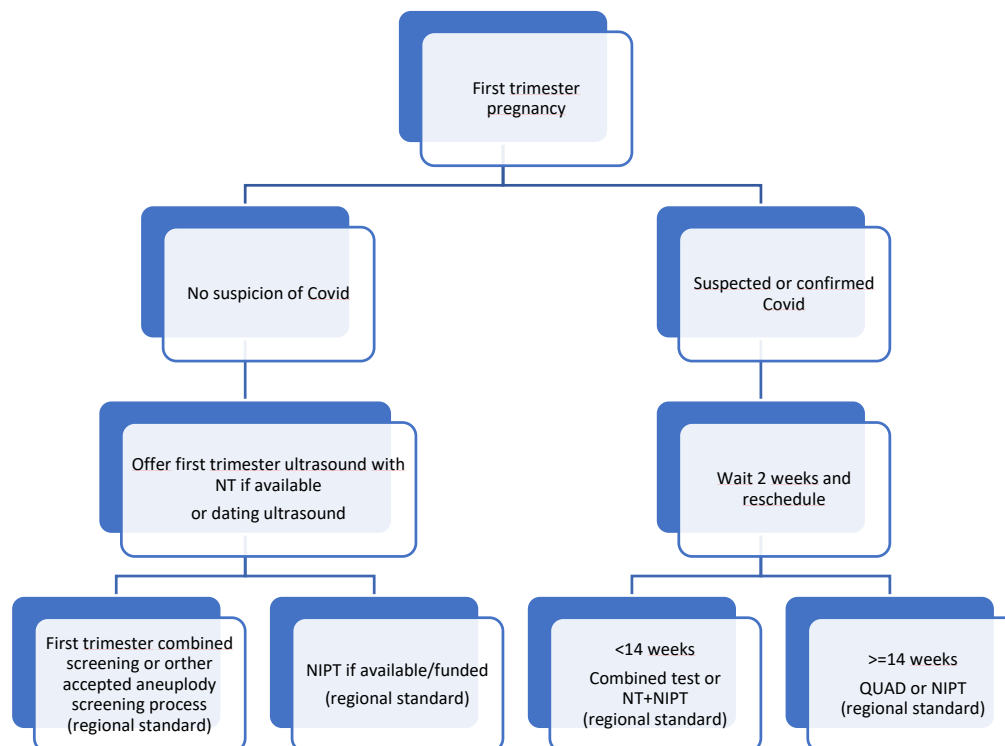
Conclusion

In the pandemic context, strategies requiring multiple screening steps or visits are obviously not ideal. Each regional prenatal screening program needs to minimize patient-health care provider contacts. For this reason, we would recommend FTS, or NIPT where available and funded, be the first choice of screening for all pregnant women with available NT ultrasound. These tests should be performed after the 11-14 weeks scan in order to minimize unnecessary blood tests (non-viable pregnancies or gross anomalies requiring diagnostic tests rather than screening tests). QUAD screening may be offered to women presenting after 14 weeks (due to late booking and/or quarantine), or in areas without the first-trimester screening availability or funded NIPT.

As an example, Ontario has provided temporary measures for Prenatal Screening during the COVID-19 Pandemic: <https://www.bornontario.ca/en/psa/about-prenatal-screening/prenatal-screening-and-covid-19.aspx>

Figure 1 summarizes the options that we propose.

Figure 1. Proposed strategy for prenatal screening during the COVID-19 pandemic.



NT: nuchal translucency ultrasound; NIPT: non-invasive prenatal testing; QUAD: quadruple second trimester serum screening.

References

1. Buekens P, Alger J, Breart G, Cafferata ML, Harville E, Tomasso G. A call for action for COVID-19 surveillance and research during pregnancy. *Lancet Glob Health* 2020.
2. Elshafeey F, Magdi R, Hindi N, et al. A systematic scoping review of COVID-19 during pregnancy and childbirth. *Int J Gynaecol Obstet* 2020.
3. Dashraath P, Wong JIJ, Lim MXK, et al. Coronavirus disease 2019 (COVID-19) pandemic and pregnancy. *Am J Obstet Gynecol* 2020.
4. Rasmussen SA, Jamieson DJ. Coronavirus Disease 2019 (COVID-19) and Pregnancy: Responding to a Rapidly Evolving Situation. *Obstet Gynecol* 2020;135:999-1002.
5. Rasmussen SA, Smulian JC, Lednický JA, Wen TS, Jamieson DJ. Coronavirus Disease 2019 (COVID-19) and pregnancy: what obstetricians need to know. *Am J Obstet Gynecol* 2020.
6. Audibert F, De Bie I, Johnson JA, et al. No. 348-Joint SOGC-CCMG Guideline: Update on Prenatal Screening for Fetal Aneuploidy, Fetal Anomalies, and Adverse Pregnancy Outcomes. *J Obstet Gynaecol Can* 2017;39:805-17.
7. Karim JN, Roberts NW, Salomon LJ, Papageorghiou AT. Systematic review of first-trimester ultrasound screening for detection of fetal structural anomalies and factors that affect screening performance. *Ultrasound Obstet Gynecol* 2017;50:429-41.
8. Nevo O, Brown R, Glanc P, Lim K. No. 352-Technical Update: The Role of Early Comprehensive Fetal Anatomy Ultrasound Examination. *J Obstet Gynaecol Can* 2017;39:1203-11.
9. Abu-Rustum RS, Akolekar R, Sotiriadis A, et al. ISUOG Consensus Statement on organization of routine and specialist obstetric ultrasound services in the context of COVID-19. *Ultrasound Obstet Gynecol* 2020.
10. Bourne T, Kyriacou C, Coomarasamy A, et al. ISUOG Consensus Statement on rationalization of early-pregnancy care and provision of ultrasonography in context of SARS-CoV-2. *Ultrasound Obstet Gynecol* 2020.
11. Huang T, Meschino WS, Teitelbaum M, Dougan S, Okun N. Enhanced First Trimester Screening for Trisomy 21 with Contingent Cell-Free Fetal DNA: A Comparative Performance and Cost Analysis. *J Obstet Gynaecol Can* 2017;39:742-9.
12. Bujold E, Okun N, Johnson JA, Audibert F. Beyond Fetal Aneuploidy: A Call For A Contemporary Canadian Approach To Prenatal Screening. *J Obstet Gynaecol Can* 2018;40:273-5.