

# Sonographic Measurement of the Lower Uterine Segment Thickness: Is it Truly Predictive of Uterine Rupture?

Vincent Y.T. Cheung, MBBS, FRCOG, FRCSC

Department of Obstetrics and Gynaecology, North York General Hospital, University of Toronto, Toronto ON

## Abstract

**Background:** Sonographic examination of the lower uterine segment (LUS) has been used to diagnose a uterine defect and to determine the degree of LUS thinning in women with previous Caesarean section. Previous studies have demonstrated that the LUS thickness measured sonographically has a high negative predictive value for uterine rupture, suggesting that a normal LUS thickness predicts a safe trial of vaginal birth after previous Caesarean section (VBAC). However, the clinical application of LUS measurement in the management of VBAC remains controversial. Because uterine rupture is rare and the number of women willing to attempt VBAC is declining, it would be difficult to recruit sufficient patients for an adequate sample size when designing studies to evaluate LUS measurement in predicting uterine rupture.

**Case:** A healthy 34-year-old, gravida 7, para 5, had a lower segment transverse Caesarean section for her fifth delivery. She underwent a trial of VBAC for her subsequent pregnancy. Despite a normal sonographic LUS evaluation at 37 weeks' gestation, she had uterine rupture during labour.

**Conclusion:** Clinical experience with the use of LUS measurement in predicting uterine rupture and managing VBAC is limited. Having a national registry to record data and review all cases of uterine rupture would accelerate the accumulation of experience on this subject.

## Résumé

**Contexte :** L'examen échographique du segment utérin inférieur (SUI) a été utilisé pour diagnostiquer une anomalie utérine et déterminer le degré d'amincissement du SUI chez les femmes ayant déjà connu une césarienne. Les études précédentes avaient démontré que l'épaisseur du SUI déterminée de façon échographique présentait un coefficient élevé de prévision d'un test négatif en ce qui concerne la rupture utérine, laissant ainsi entendre qu'une épaisseur normale de SUI permettait de prédire la sûreté d'une tentative d'accouchement vaginal après une césarienne (AVAC). Néanmoins, la mise en œuvre clinique de la mesure du SUI dans le cadre de la prise en charge de l'AVAC

demeure controversée. Puisque la rupture utérine est un phénomène rare et que le nombre de femmes disposées à tenter un AVAC est en baisse, il serait difficile de recruter un nombre suffisant de patientes pour obtenir un échantillon adéquat afin de concevoir des études visant à évaluer le rôle de la mesure du SUI dans la prévision d'une rupture utérine.

**Cas :** Une femme en santé de 34 ans, gravida 7, para 5, avait subi une césarienne segmentaire transversale dans le cadre de son cinquième accouchement. Elle a subi une tentative d'AVAC dans le cadre de sa grossesse suivante. Malgré le fait qu'un examen échographique mené à la 37<sup>e</sup> semaine de gestation ait constaté la présence d'un SUI normal, la patiente a connu une rupture utérine pendant le travail.

**Conclusion :** L'expérience clinique est limitée en ce qui concerne l'utilisation de la mesure du SUI pour la prévision d'une rupture utérine et la prise en charge de l'AVAC. La mise sur pied d'un registre national destiné à la consignation des données et à l'analyse de tous les cas de rupture utérine permettrait d'accélérer l'accumulation d'expérience à ce sujet.

J Obstet Gynaecol Can 2008;30(2):148–151

## INTRODUCTION

Sonographic measurement of the LUS has been used in predicting uterine rupture in women with previous CS.<sup>1–7</sup> However, its value in the management of a trial of VBAC is still controversial.

## THE CASE

A healthy 34-year-old healthy gravida 7, para 5, had had four uncomplicated singleton pregnancies resulting in spontaneous vaginal deliveries of healthy infants weighing between 3220 and 4490 g. She had undergone bilateral tubal ligation after her fourth delivery, and had reversal of sterilization performed five years later. She conceived one year after her reversal of sterilization and had an uneventful antenatal course, but then had a low segment transverse CS for cephalopelvic disproportion. She had an 11-hour labour, and her cervix did not dilate beyond 5 cm with an unengaged presenting part. A healthy female infant weighing 4116 g was delivered.

**Key Words:** Caesarean section, lower uterine segment thickness, sonography, ultrasound, uterine rupture, vaginal birth after Caesarean section, VBAC

Competing Interests: None declared.

Received on July 3, 2007

Accepted on September 24, 2007

Her next pregnancy was uneventful, and she had an estimated date of delivery approximately 22 months after her previous CS. She indicated a wish to attempt a vaginal birth. Sonographic examination was performed at 37 weeks' gestation using an Aloka SSD-5500 ultrasound machine with a 3.5-MHz convex transabdominal and a 7.5 MHz transvaginal transducer. The estimated fetal weight was 3348 g. Sonographic examination and measurement of the LUS was performed as previously described.<sup>1,2</sup> There was no sonographic evidence of dehiscence. The LUS thickness (excluding the bladder mucosa) measured 1.6 mm transabdominally (Figure 1) and 2.8 mm transvaginally (Figure 2). These measurements were greater than the cut-off value used (> 1 mm) to allow VBAC, based on previous reports.<sup>1,7</sup> After appropriate counselling, the woman accepted the risks of VBAC and was willing to attempt a trial of vaginal birth.

She went into spontaneous labour at 40 weeks' gestation. Her labour progressed to 7 cm cervical dilatation, at which point her cervix was found to be edematous, and continuous fetal heart rate monitoring showed an elevated baseline heart rate. Immediate CS was performed, during which uterine rupture was noted, with extension of the ruptured scar laterally close to the left ureter. The defect was repaired. Because of extensive adhesions, there was significant bleeding from the operation site, and two units of blood were transfused during the surgery. The infant weighed 3945 g and had Apgar scores of 9 and 9 at 1 and 5 minutes respectively. Umbilical cord arterial blood taken was insufficient for pH measurement. The patient had an uneventful recovery and was discharged home on the fourth postoperative day.

## DISCUSSION

Uterine rupture is a recognized complication of a trial of VBAC. In a recent guideline on VBAC, the Society of Obstetricians and Gynaecologists of Canada recommended that, in the absence of any contraindications, a woman with one previous transverse lower segment CS should be offered a trial of labour with appropriate discussion of maternal and perinatal risks and benefits.<sup>8</sup> At present, there are still no reliable methods for predicting the risk of uterine rupture in women attempting VBAC. Sonographic measurement of the LUS has been used in estimating the risk of uterine rupture, but the value of using this measurement in

the management of VBAC remains controversial.<sup>1-7</sup> In Canada, it is still not a popular practice to use LUS measurement in the management of women with previous CS.<sup>9</sup>

Sonographically, the LUS appears as a two-layered structure that consists of the echogenic muscularis and the mucosa of the bladder wall, including part of the visceral-parietal peritoneum, and the relatively hypoechoic myometrial layer (Figures 1 and 2). In most studies, the ultrasound examination has been performed at between 36 and 38 weeks' gestation with a full urinary bladder to allow good imaging of the LUS.<sup>1-4,7</sup> Sonographic evaluation of the LUS can determine the degree of LUS thinning and identify a dehiscence (defined as subperitoneal separation of the uterine scar, with chorioamniotic membrane visible through the peritoneum of the LUS).<sup>1-7</sup> Although the morbidity of dehiscence is clinically much less than rupture, prenatal identification of an extremely thin or a dehiscence LUS is believed to be predictive of subsequent uterine rupture during labour.<sup>5,7</sup> Both transabdominal and transvaginal examinations to measure the LUS have been described.<sup>1-7,10,11</sup> Generally, transvaginal examination permits good visualization of the LUS mainly in the pericervical area, whereas the transabdominal approach allows better visualization of the whole LUS. Sen et al. showed a strong interclass correlation (0.965) between transabdominal and transvaginal sonography in measuring the LUS thickness.<sup>4</sup> However, recent studies suggest that a transvaginal study is more reproducible between observers than a transabdominal study.<sup>10,11</sup>

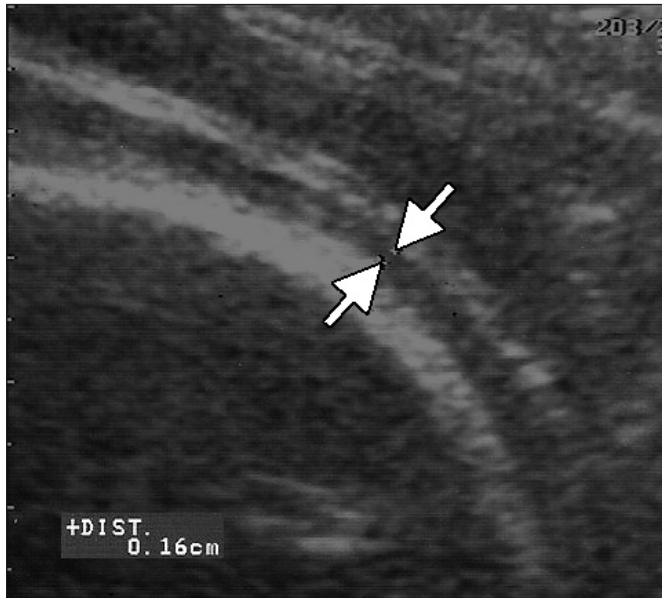Different LUS measuring techniques have been described.<sup>1-7</sup> Some authors measure the full LUS thickness,<sup>3,4</sup> whereas others measure only the myometrial layer.<sup>1,2,7</sup> However, irrespective of the various measuring techniques used, most studies have demonstrated a strong negative predictive value (90.9% to 100%) in predicting uterine rupture, suggesting that a normal LUS thickness is a strong indicator for safe VBAC.<sup>1,3-7</sup> Rozenberg et al. published the largest series of 642 women with previous CS and demonstrated that the risk of a uterine scar being defective increased significantly when the full LUS thickness was 3.5 mm or less, with a negative predictive value of 99.3%.<sup>3</sup> In a series of 102 Canadian patients, measuring only the myometrial layer and using a cut-off value of = 1.0 mm in assessing women with previous CS, negative and positive predictive values of 90.9% and 81.2% respectively were calculated.<sup>1</sup>

Sonography permits accurate assessment of the LUS thickness in women with previous CS and can potentially be used to predict the risk of uterine rupture during trial of vaginal birth.<sup>1</sup> However, because uterine rupture is rare and the number of women willing to attempt VBAC is declining, it is difficult for a single institution to accumulate enough

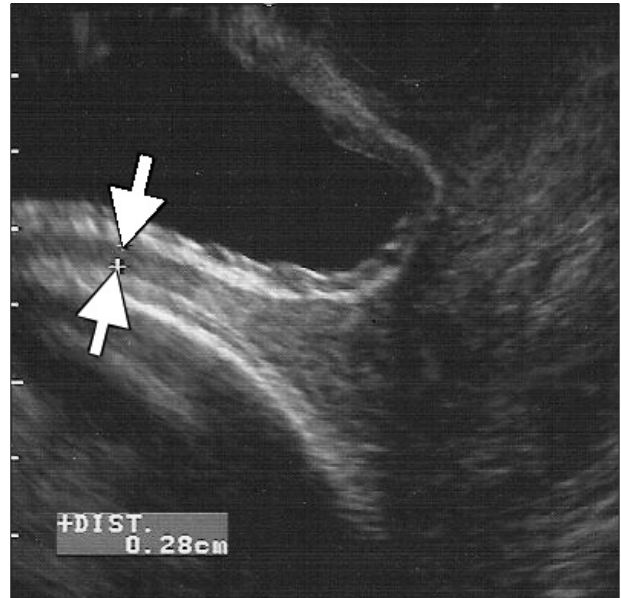
## ABBREVIATIONS

CS	Caesarean section
LUS	lower uterine segment
VBAC	vaginal birth after Caesarean section

**Figure 1. Transabdominal longitudinal sonogram showing the LUS thickness of 1.6 mm (between arrows).**



**Figure 2. Transvaginal longitudinal sonogram showing the LUS thickness of 2.8 mm (between arrows).**



experience to achieve a valid conclusion when addressing the use of LUS measurement in the management of VBAC. Similarly, it is unlikely that a prospective randomized study will be conducted of women with different LUS thicknesses in labour, because it would be difficult to achieve an adequate sample size; in addition, it would be potentially dangerous to encourage a woman with an extremely thin LUS to undergo labour. Physicians will need to rely on case reports and case series to accumulate experience with use of LUS measurement in VBAC management.

Contrary to studies showing a strong negative predictive value when LUS measurement was used to predict uterine rupture,<sup>1,3-7</sup> this case had an unexpected outcome. The outcome of the case emphasizes the potential limitations of using LUS measurement for VBAC in women who have had previous vaginal births. Multiparous women have a thicker LUS than nulliparous women.<sup>2</sup> The experience in this case suggests that women who have had previous vaginal births in addition to a CS may have a thicker LUS measurement than those who have not had vaginal births. However, the thicker LUS in women with previous vaginal births may not directly reflect the integrity of the LUS, and possibly a greater cut-off value should be used for predicting uterine rupture. Unfortunately, no studies have compared the LUS thickness in women who have had previous CS with and without vaginal births, and the appropriate cut-off value to be used in women with previous vaginal births will need to be determined in further studies.

Women with previous CS will often make their own choice regarding route of delivery. If they choose VBAC, part of the role of their obstetrical care providers is to ensure that they will have a safe labour. Although LUS measurement can potentially be used as a tool to determine the risk of uterine rupture, other factors may operate to influence the accuracy of this tool. In this case, the patient had a short interval between deliveries, and this is known to be associated with a higher risk of rupture.<sup>12,13</sup> However, no studies have been performed to evaluate the LUS thickness in women with different interdelivery intervals. Although LUS measurement has potential to predict uterine rupture, we still cannot use it with confidence in the management of VBAC.

Cases with unexpected outcomes are generally undesirable, but they can provide an educational message for health care providers. Experience from a single case cannot be generalized; but, because uterine rupture is rare, we have to rely on case reports and case series to accumulate adequate knowledge. Most clinical tests have limitations, and the use of LUS measurement in women with previous vaginal births may be potentially unreliable in predicting uterine rupture. In the absence of more reliable evidence to support or refute this speculation, obstetrical care providers should be encouraged to utilize sonographic LUS measurement in the management of VBAC and to report cases with unexpected outcomes. Establishing a national registry to record and review all cases of uterine rupture occurring in Canada, possibly under the auspices of the Society of Obstetricians and Gynaecologists of Canada, would accelerate the

accumulation of reliable data. This registry would facilitate sharing of experience on this subject among health care providers.

### **ACKNOWLEDGEMENTS**

The woman whose story is told in this report has provided signed consent for its publication.

The author wishes to thank Ms Judy Rogers, RM, the midwife attending the woman whose story is told in this report.

### **REFERENCES**

1. Cheung VYT. Sonographic measurement of the lower uterine segment thickness in women with previous Caesarean section. *J Obstet Gynaecol Can* 2005;27:674–81.
2. Cheung VYT, Constantinescu OC, Ahluwalia BS. Sonographic evaluation of the lower uterine segment in patients with previous cesarean delivery. *J Ultrasound Med* 2004;23:1441–7.
3. Rozenberg P, Goffinet F, Philippe HJ, Nisand I. Ultrasonographic measurement of lower uterine segment to assess risk of defects of scarred uterus. *Lancet* 1996;347:281–4.
4. Sen S, Malik S, Salhan S. Ultrasonographic evaluation of lower uterine segment thickness in patients of previous cesarean section. *Int J Gynaecol Obstet* 2004;87:215–9.
5. Gotoh H, Masuzaki H, Yoshida A, Yoshimura S, Miyamura T, Ishimaru T. Predicting incomplete uterine rupture with vaginal sonography during the late second trimester in women with prior cesarean. *Obstet Gynecol* 2000;95:596–600.
6. Michaels WH, Thompson HO, Boutt A, Schreiber FR, Michaels SL, Karo J. Ultrasound diagnosis of defects in the scarred lower uterine segment during pregnancy. *Obstet Gynecol* 1988;71:112–20.
7. Asakura H, Nakai A, Ishikawa G, Suzuki S, Araki T. Prediction of uterine dehiscence by measuring lower uterine segment thickness prior to the onset of labor. Evaluation by transvaginal ultrasonography. *J Nippon Med Sch* 2000;67:352–6.
8. Martel MJ, MacKinnon CJ. Guidelines for vaginal birth after previous Caesarean birth. SOGC Clinical Practice Guidelines, No. 155, February 2005. *J Obstet Gynaecol Can* 2005;27:164–74.
9. Brill Y, Kingdom J, Thomas J, Fraser W, Milne JK, Thomas M, et al. The management of VBAC at term: a survey of Canadian obstetricians. *J Obstet Gynaecol Can* 2003;25:300–10.
10. Jastrow N, Antonelli E, Robyr R, Irion O, Boulvain M. Inter- and intraobserver variability in sonographic measurement of the lower uterine segment after a previous Cesarean section. *Ultrasound Obstet Gynecol* 2006;27:420–4.
11. Allen V, Robinson H, Baskett T, Armson A, McLeod L, Scott M, et al. Ultrasonographic measurement of the lower uterine segment: reliability and effect of gestational age. *J Obstet Gynaecol Can* 2007;29(Suppl):S29.
12. Shipp TD, Zelop CM, Repke JT, Cohen A, Lieberman E. Interdelivery interval and risk of symptomatic uterine rupture. *Obstet Gynecol* 2001;97:175–7.
13. Bujold E, Mehta SH, Bujold C, Gauthier R. Interdelivery interval and uterine rupture. *Am J Obstet Gynecol* 2002;187:1199–202.