

Removal of a Non-Communicating Horn May Not Affect Persistence or Recurrence of Endometriosis: A Case Report

Elizabeth L. Taylor, MD, Peter F. McComb, MB BS

Division of Reproductive Endocrinology and Infertility, Department of Obstetrics and Gynaecology, University of British Columbia, Vancouver BC

Abstract

Background: Retrograde menstruation is thought to initiate and potentiate endometriosis in women with non-communicating uterine anomalies. The effect of removing a non-communicating uterine horn on the persistence or recurrence of endometriosis is unknown.

Case: A 29-year-old woman with a non-communicating uterine horn and endometriosis underwent surgical removal of the non-communicating horn with cautery of the endometriosis. A laparoscopy done two years later showed endometriosis similar in stage to that found at the initial procedure.

Conclusion: Removal of a non-communicating uterine horn in a woman with endometriosis did not reduce the risk of persistence or recurrence of the disease.

Résumé

Contexte : On soupçonne que les menstruations rétrogrades provoquent et potentialisent l'endométriose chez les femmes qui présentent des anomalies utérines non communicantes. L'effet de l'excision d'une corne utérine non communicante sur la persistance ou la récurrence de l'endométriose est inconnu.

Cas : Une femme de 29 ans présentant une corne utérine non communicante et une endométriose a été soumise à une excision chirurgicale de la corne non communicante et à une cautérisation de l'endométriose. Une laparoscopie, effectuée deux ans plus tard, a indiqué la présence d'une endométriose de stade similaire à celui qui avait été constaté au moment de l'intervention initiale.

Conclusion : L'excision d'une corne utérine non communicante chez une femme présentant une endométriose n'a pas entraîné une diminution du risque de persistance ou de récurrence de la maladie.

J Obstet Gynaecol Can 2007;29(3):247-249

INTRODUCTION

Endometriosis is present in up to 10% of reproductive age women.¹ The prevalence is higher among women with congenital uterine anomalies.² In women with non-communicating anomalies that contain functional endometrial tissue, such as a unicornuate uterus with a non-communicating uterine horn, transcervical expulsion of menstrual debris is not possible. On the other hand, retrograde expulsion is possible and, as Sampson theorized in 1927, may lead to intraperitoneal implantation of endometrial fragments.³ Accordingly, interventions that reduce the efflux of menstrual debris from the anomalous cavity into the pelvis may allow improvement in endometriosis.

We report here our findings in a patient with a unicornuate uterus, a non-communicating horn, and endometriosis who underwent surgical removal of the horn.

THE CASE

A 29-year-old nulligravid woman presented with a four-year history of pelvic pain that was especially severe at the time of menses. Two previous laparoscopies had demonstrated a right unicornuate uterus with a non-communicating left horn (American Society for Reproductive Medicine [ASRM] class IIb) and ASRM Stage I and II endometriosis. All visible endometriosis was cauterized at the time of each laparoscopy (Table).

The patient's medical, surgical, and family histories were unremarkable. At pelvic examination, a single cervix was identified, and two separate uterine bodies could be palpated. Hysterosalpingography demonstrated a single cervix leading to a right unicornuate uterus with no communication to the left horn.

The non-communicating horn was considered to be the cause of the patient's severe dysmenorrhea through

Key Words: Uterus, unicornuate, non-communicating uterine horn, endometriosis

Competing Interests: None declared.

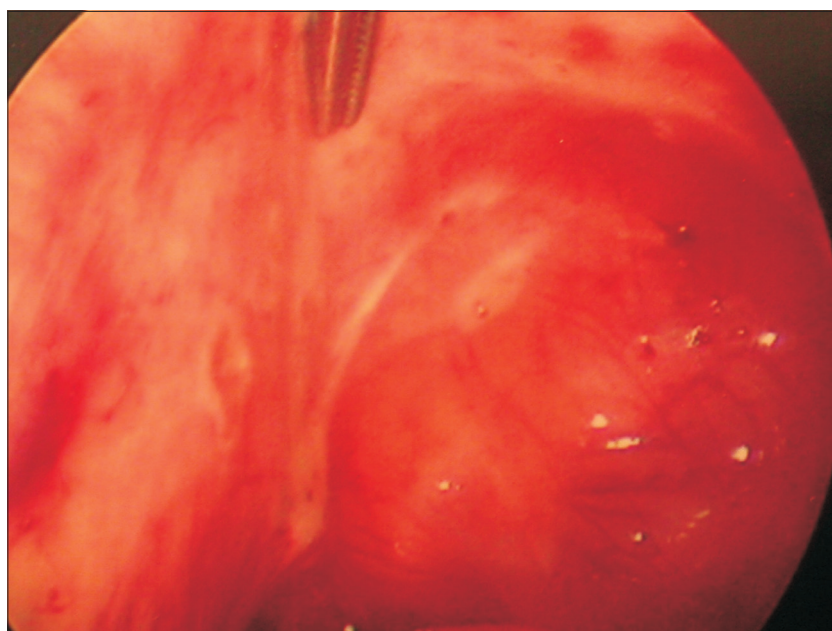
Received on September 12, 2006

Accepted on November 8, 2006

Course of disease in a patient with a non-communicating uterine horn

Age	Event	ASRM Stage
23	Onset of pelvic pain	
	Laparoscopy cauterization of endometriosis	I
26	Recurrent pain	
32	Laparoscopy cauterization of endometriosis	II
33	Excision of left non-communicating horn	II
	Cauterization of endometriosis	
36	Recurrent pain	
	Laparoscopy cauterization of endometriosis	II

Laparoscopy at age 33. Bipolar cautery of culdesac endometriosis that persisted or reoccurred after removal of the non-communicating functional uterine horn



intracavitary retention of menstrual effluent and retrograde menstrual flow. For this reason, she underwent laparotomy with surgical removal of the left uterine horn. ASRM Stage II endometriosis was identified and cauterized.

After removal of the horn, the patient was free of pelvic pain for two years, but thereafter she had a recurrence that was similar in quality to the previous pain. Laparoscopy was performed, and ASRM Stage II endometriosis was identified and cauterized (Figure). Present, but not reflected in the staging, was the *de novo* finding of nodular endometriosis of the sigmoid colon.

DISCUSSION

A unicornuate uterus is found in 0.4% of reproductive age women and is associated with endometriosis in up to 40%

of cases.²⁴ In order to advise women with such an uncommon condition about their risk of developing endometriosis, we rely upon our understanding of the pathogenesis of the disease.

Although there are many theories of the pathogenesis of endometriosis, a widely accepted theory is that of retrograde menstruation, postulated by Sampson. In keeping with this theory, removal of a non-communicating uterine horn should decrease the amount of menstrual debris reaching the peritoneal cavity and thus reduce the severity of endometriosis. Further, if cautery of endometrial implants successfully decreases or eliminates the disease, our patient should have shown reduced severity of disease at laparoscopy two years later. Yet we observed a pattern of disease similar to that observed before removal of the

non-communicating horn, suggesting that the intervention may have had no long-standing effect on the endometriosis.

In previous reviews of this subject, removal of a non-communicating horn is recommended to reduce the risk of recurrent or *de novo* endometriosis.⁵⁻⁹ This recommendation is not based on published evidence of benefit, but upon assumptions of the pathogenesis of disease. Indeed this case report is, to our knowledge, the first report of pelvic assessment after removal of a non-communicating uterine horn. As there was no improvement in the severity of endometriosis after horn removal, routine removal of a non-communicating horn should be reconsidered.

In our case, removal of the horn, thought to be the instigator of the endometriosis, did not eradicate the endometriosis. Once endometriosis has been established, other factors such as genetics, the environment, and the immune system may be determinants of persistence or progression of the disease. It appears that removal of the non-communicating horn with surgical treatment of all visible endometriosis cannot assure a woman that her endometriosis will not recur or persist in the future.

ACKNOWLEDGEMENTS

The woman whose story is told in this case report has provided signed permission for its publication.

REFERENCES

1. Speroff L, Fritz M. Clinical gynecologic endocrinology and infertility. 7th ed. New York: Lippincott, Williams and Wilkins; 2005.
2. Heinonen PK. Unicornuate uterus and rudimentary horn. *Fertil Steril* 1997;68:224-30.
3. Sampson JA. Peritoneal endometriosis due to menstrual dissemination of endometrial tissue into the peritoneal cavity. *Am J Obst Gynecol* 1927;14:422-69.
4. Acien P. Incidence of mullerian defects in fertile and infertile women. *Hum Reprod* 1997;12:1372-6.
5. Buttram VC Jr, Gibbons WE. Mullerian anomalies: a proposed classification (An analysis of 144 cases). *Fertil Steril* 1979;32:40-6.
6. Olive DL, Henderson DY. Endometriosis and mullerian anomalies. *Obstet Gynecol* 1987;69:412-5.
7. Canis M, Wattiez A, Pouly J, Mage G, Manhes H, Bruhat MA, et al. Laparoscopic management of unicornuate uterus with rudimentary horn and unilateral extensive endometriosis: case report. *Hum Reprod* 1990;5:819-20.
8. Nezhat F, Nezhat C, Bess O, Nezhat CH. Laparoscopic amputation of a noncommunicating rudimentary horn after a hysteroscopic diagnosis: a case study. *Surg Laparosc Endosc* 1994;4:155-6.
9. Fujimoto VY, Klein NA, Miller PB. Late-onset hematometra and hematosalpinx in a woman with a noncommunicating uterine horn. A case report. *J Reprod Med*. 1998;43:465-7.